

January 19th, 2017

**RE: Denise Richards**  
MR#: 3731770  
DOB: SEP 9, 1983  
(Exam #: R110560-U-1-2)  
(HIS ID #: 52469524238)

**To: Mackenzie Bednar, M.D.**  
1111 Williams Street  
Orange, CA 92777

The LMP of this 33 year old, gravida 2, para 1 patient was AUG 22 2016, giving her an EDD of MAY 29 2017 and a current gestational age of 21 weeks 3 days by dates. The ultrasound examination was performed using abdominal & vaginal techniques. The patient has a BMI of 29.1.

Multiple longitudinal and transverse sections revealed a singleton intrauterine pregnancy with the fetus in transverse presentation. The placenta is anterior in implantation, grade 0 in appearance, and there is no placenta previa.

**PLACENTA**

Fetus # 1 of 1	No placenta previa
Transverse presentation	Placenta Grade = 0
Placenta Location = Anterior	

**INDICATIONS**

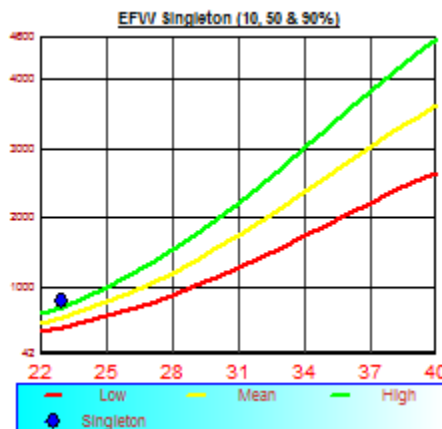
Previous child with congenital anomalies

**Exam Types**

Transvaginal ultrasound (76817) (Quantity: 1)

**MEASUREMENTS**

<b>AC</b>	14.9 cm	20 weeks 1 day *	[11%]
<b>BPD</b>	4.7 cm	20 weeks 1 day *	[12%]
<b>HC</b>	17.3 cm	19 weeks 6 days *	[<5%]
<b>Femur</b>	3.3 cm	20 weeks 4 days *	[17%]
<b>Humerus</b>	3.2 cm	20 weeks 5 days	[26%]
<b>Radius</b>	2.6 cm	20 weeks 5 days	
<b>Ulna</b>	3.0 cm	21 weeks 1 day	
<b>Tibia</b>	2.7 cm	19 weeks 5 days	[<5%]
<b>Fibula</b>	2.8 cm	19 weeks 3 days	
<b>Cerebellum</b>	2.1 cm	20 weeks 3 days	
<b>CisternaMagna</b>	0.7 mm		
<b>HC/AC</b>	1.16		
<b>FL/AC</b>	0.22		
<b>FL/BPD</b>	0.70		
<b>EFW (Ac/FI/Hc)</b>	335grams - 0 lbs 12 oz		



**THE AVERAGE GESTATIONAL AGE is 20 weeks 1 day ± 10 days.**

**ANATOMY**

	Normal	Abnormal	Not Visualized	Suboptimal	See Details
Head	✓				
Face/Neck	✓				
Th. Cav.	✓				
Heart	✓				

	Normal	Abnormal	Not Visualized	Suboptimal	See Details
Abd. Cav.	✓				
Stomach	✓				
Right Kidney	✓				
Left Kidney	✓				
Bladder	✓				
Abd. Wall	✓				
Spine	✓				
Extrems	✓				
Genitalia			?		
Placenta Appearance	✓				
Umbil. Cord	✓				
PCI			?		

**ANATOMY DETAILS**

**Visualized Appearing Sonographically Normal:**

HEAD: (BPD Level, Lateral Ventricles, Choroid Plexus, Cerebellum, Cisterna Magna); FACE/NECK: (Neck, Nuchal Fold, Profile, Orbits, Nose/Lips, Palate, Face); TH. CAV.: (Diaphragm); HEART: (Four Chamber View, Proximal Left Outflow, Proximal Right Outflow, Short Axis of Greater Vessels, Cardiac Axis, Interventricular Septum, Interatrial Septum, Cardiac Position); ABD. CAV., STOMACH, RIGHT KIDNEY, LEFT KIDNEY, BLADDER, ABD. WALL, SPINE: (Cervical Spine, Thoracic Spine, Lumbar Spine, Sacrum); EXTREMS: (Lt Humerus, Rt Humerus, Lt Forearm, Rt Forearm, Lt Hand, Rt Hand, Lt Femur, Rt Femur, Lt Low Leg, Rt Low Leg, Lt Foot, Rt Foot); PLACENTA, UMBL. CORD

**Suboptimally Visualized:**

HEAD: (Calvarium)

**Not Visualized:**

GENITALIA, PCI

**CERVICAL EVALUATION**

**SUPINE**

Cervical Length: 3.30 cm

**OTHER TEST RESULTS**

Funneling?: No                      Dynamic Changes?: No  
Resp. To TFP?: No

**UTERUS**

The uterus was well visualized, midplane & anteverted in orientation.

**ADNEXA**

Both ovaries appeared normal.

**AMNIOTIC FLUID**

3.2	3.1	AFI Total = 12.7
2.1	4.3	Amniotic Fluid: Normal

**IMPRESSION**

Twin IUP (Fetus A)  
Transverse presentation  
Anterior placenta  
No placenta previa  
Estimated Fetal Weight = 335 grams  
Estimated Fetal Weight = 0 lbs 12 oz

**RECOMMENDATION**

Ultrasound: 4 Weeks

Betsy Larkin, R.D.M.S

Wilma Nikolaus, M.D.  
Report is preliminary unless signature is present.

**IMAGES**

